

Qalqonsimon bezning nodulyar patologiyasini differentsial tashxislashda ultratovushli elastografiya

*O'sarov Muhridin Shuhratovich, Iskandarova Sabina Xasan qizi
Samarqand Davlat tibbiyot universiteti, Samarqand, O'zbekiston.*

Maqsad: Ushbu ish qalqonsimon bezning nodulyar xosilalarini differentsial tashxislashda ultratovush elastografiyasidan foydalangan holda multiparametrik ultratovushning informatsion qiymatini aniqlash edi.

Tadqiqot materiallari va usullari. Ishda 229 nafar bemorga operatsiyadan oldingi tayyorgarlik bosqichida o'tkazilgan multiparametrik ultratovush tekshiruv natijalari tahlil qilindi. Tadqiqotning maqsadi sifatida ARFI va kuchlanish nisbati yordamida kompresion elastografiyasi (KEG) va to'lqinli elastografiyasi (TEG) samaradorligini baholashdir. Bemorlarning ikki guruhi ajratiladi: birinchi guruh (N1 = 93) - qalqonsimon bez saratoni bilan og'rigan bemorlar. ikkinchisi (N2 = 136) - qalqonsimon bezning yaxshi tugunli xosilalari (qalqonsimon bezning adenomasi va follikulyar yoki kolloidli zob). Nazorat guruhi qalqonsimon bez parenximasi o'zgarmagan 174 bemordan iborat. KEG paytida to'qimalarning elastikligi ma'lum ranglarda ko'rsatilgan (ranglarni kartirlash). SonoScape S50 (Xitoy), Mindray Consona N9 (Mindray, Xitoy), Mindray resona i9 (Mindray, Xitoy) ultratovush qurilmalarida amalga oshirilgan ARFI va kuchlanish nisbati rejimlarida kesish to'lqin elastografiyasi (SWE) ishlatilgan.

Natijalar. Bizning ma'lumotlarimiz natijalariga ko'ra, KEG rejimida o'zgarmagan qalqonsimon bezning parenximasi geteroexogen, notekis nozik, o'rta donali simmetrik bo'yaladi (96,6%). Qalqonsimon bez saratonida kesish to'lqinining tezligi (ARFI) 3,57 m / s dan katta va zichlik nisbati indeksi (elastiklik moduli, kuchlanish nisbati) 1,56 dan yuqori.

Xulosa: Qalqonsimon bezning nodulyar neoplazmalarini kompleks tashxislashda TEGdan foydalanish juda informatsiondir, shuning uchun qalqonsimon bezda o'sma shakllanishlar mavjudligiga shubha tug'ilganda, tugunlarning o'lchami aniqlanganda va atrofdagi to'qimalarga o'sma kirib borishi

Kalit soʻzlar: nodulyar neoplazmalar, qalqonsimon bez saratoni, multiparametrik ultratovush, kompresion elastografiyasi, toʻlqinli elastografiya.

Kirish. Soʻnggi yillarda radiatsion diagnostika usullarining imkoniyatlari ancha oldinga qadam tashladi va bugungi kunda ichki va yuzaki organlarni, shu jumladan qalqonsimon bez kasalliklarini (qalqonsimon bez) operatsiyadan oldingi diagnostika bosqichida etakchi rol oʻynaydi. Maʼlumki, koʻp parametrlil ultratovush tekshiruvini aniqlashda radiodiagnostikaning asosiy usuli hisoblanadi. Ammo davolash taktikasini shakllantirish uchun qalqonsimon bezning tugunli neoplazmalarini differentsial diagnostika qilishda zamonaviy multiparametrik ultratovush variantlarini kompleks qoʻllash samaradorligini baholash, shuningdek, jarrohlik aralashuvining zarurati va koʻlami masalasini hal qilish masalasi hali ham dolzarbligicha qolmoqda.

Qalqonsimon bezning nodulyar patologiyasini tashxislashda ultratovushli elastografiya koʻp parametrlil ultratovushning samarali usullaridan biriga aylanmoqda. Ultratovush elastografiyasi anʼanaviy ultratovushga qoʻshimcha texnologiya boʻlib, qalqonsimon bez toʻqimalarining elastikligini baholash imkonini beradi. Komprission elastografiyasi (KEG) va toʻlqin elastografiyasi (TEG) patologik shakllanish chegaralarini, tugunlarning qattiqligi va miqdoriy xususiyatlarni aniqlashga imkon beradi, invaziv oʻsma oʻsishi chegaralari yaqinlashib kelayotgan jarrohlik amalyotlarini rejalashtirishda yordam beradi.

Tadqiqotning maqsadi: qalqonsimon bez tugunli neoplazmalarining differentsial diagnostikasida ultratovushli elastografiya yordamida multiparametrik ultratovushning informatsion qiymatini aniqlash.

Tadqiqot materiallari va usullari

Tadqiqot 229 bemorning operatsiyadan oldingi tayyorgarlik bosqichida oʻtkazilgan multiparametrik ultratovush natijalarini tahlil qildi. sonoelastografiya (SEG) samaradorligi ARFI (Acoustic Radiation Force Impulse akustik radial impulsli koʻrish) va strain ratio indikatoridan foydalanish misolida kompressiya elastografiyasi (KEG) va toʻlqinli elastografiyasi (TEG) baholandi.

Bemorlar ikki guruhga bo'lingan. 1-guruhda gistologik jihatdan tasdiqlangan saratoni bilan og'riqan bemorlar ($N_1 = 93$) to'plangan, 2-guruh ($N_2 = 136$) yaxshi Sifatli tugunlari (adenoma va follikulyar yoki kolloid tugun) bo'lgan bemorlardan iborat bo'lib, ularning tashxisi ingichka igna aspiratsiyasi biopsiyasi bilan tasdiqlangan ($n_1 = 93$).

1-guruhdagi bemorlarning yoshi 19-78 yosh oralig'ida o'zgarib turardi. Agar biz ushbu guruhdagi bemorlarning jinsi tarkibini baholasak, shuni ta'kidlash kerakki, ular orasida ayol bemorlar deyarli olti baravar ko'p (ayollarning 84,9 foizi va erkaklarning 15,1 foizi). Ushbu guruhdagi bemorlarning aksariyatiga yuqori darajada farqlangan RQB tashxisi qo'yilgan: papiller saraton 61 bemorda (65,6%), follikulyar saraton 14 bemorda (15,0%), papiller saratonning follikulyar varianti 14 bemorda (15,0%) aniqlangan. Medullar saratoni tashxisi 4 bemorga (4,4%) qo'yilgan. 2-guruhbemorlarining yosh 18-75 yoshni tashkil etdi. Ikkala guruhda ham erkaklarnikiga qaraganda ko'proq ayollar bor edi (mos ravishda 88,4 va 11,6).

Nazorat guruhi o'zgarmagan QB parenximasi bo'lgan 174 bemordan iborat edi. Barcha bemorlardan yozma ravishda xabardor qilingan rozilik olingan.

To'lqini elastografiyasi (TEG) ARFI va strain ratio rejimlarida qo'llanilgan. Acoustic Radiation Force Impulse imaging (ARFI) texnologiyasi virtual Touch Tissue Quantification rejimida Mindray Consona N9 (Mindray, Xitoy) ultratovush skanerida aniqlangan. Texnikani qo'llash jarayonida ko'ndalang to'lqin tezligi (m/s) o'lchandi. QB tugunida ko'ndalang to'lqin tezligini (ARFI) o'lchashda beshta o'lchov amalga oshirildi. Ekstremallarni olib tashlash, qolgan uchtdan o'rtacha hisoblangan.

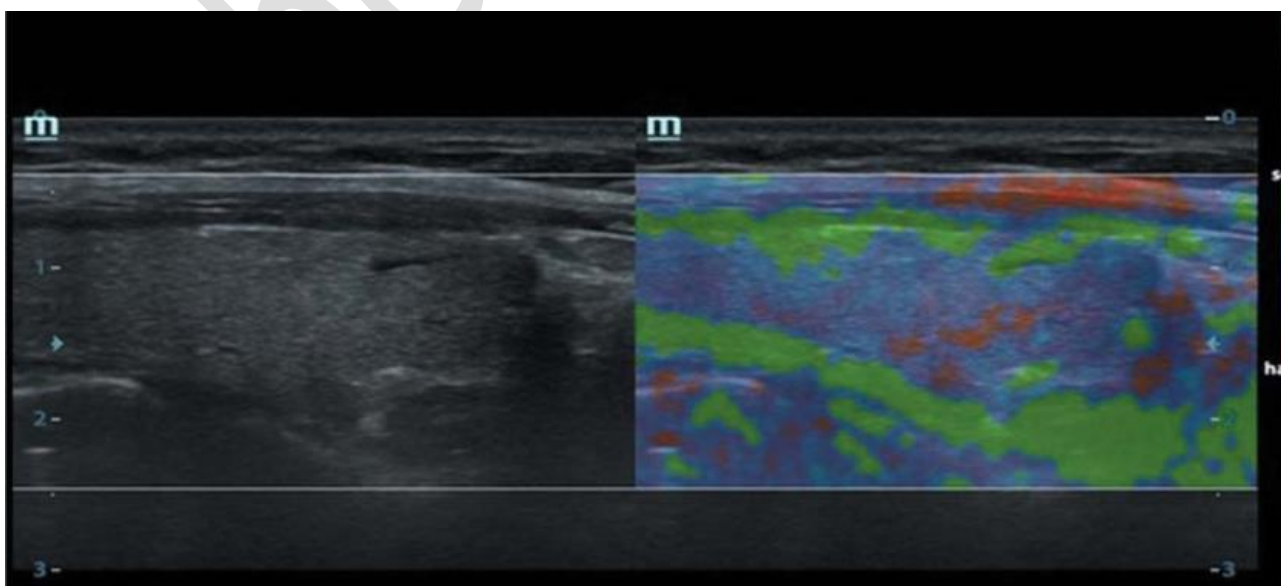
Strain Ratio indeksi Mindray risona i9 (Mindray, Xitoy) skanerlarida o'lchandi. Zichlik koeffitsienti (elastiklik moduli) shartli birliklarda aniqlandi. Strain Ratio indikatorini o'lchash — xuddi shu tugunlarining qattqlik xususiyatlari — tugun tuzilishida besh marta va tugundan kamida 1-1,5 sm masofada o'zgarmagan parenximada amalga oshirildi. Olingan minimal va maksimal o'lchov qiymatlari hisobga olinmadi va qolgan uchasi uchun ularning o'rtacha qiymati hisoblab chiqildi.

Natijalar

B rejimidan foydalanganda qalqonsimon bezning yaxshi tugunli xosilaning ultratovush belgilari quyidagilardan iborat edi: 134 holatda tekis chegaralar (99,0%), aniq konturlar — 133 (98,1%), bir hil exostruktura-126 (93,0%), tugunning oval shakli-102 (75,0%), exogenlikning pasayishi-80 (59,0%), gipoexogin maydon mavjudligi 34 (25,0%), gipexogin qo'shimchalar mavjudligi 3 (2,5%). Rangli Doppler xaritasi (RDX) rejimida 71 tugunda (52,3%) qon tomirlarining oqim kuchayishi kuzatildi, bundan tashqari, tomirlarning notekis assimetrik taqsimlanishi faqat 13 holatda (9,7%), qon tomir naqshining deformatsiyasi esa 6 holatda (4,7%) aniqlandi.

KEG rejimida (rasm. 1) o'zgarmagan QB parenximasi 168 bemorda (96,6%) geterogen, notekis mayda, o'rta donali nosimmetrik tuzulishga ega edi. 6 bemorda (3,4% hollarda) KEG bajarilmadi (parenximaning yomon ranglanishi, noqulaylik hissi haqida shikoyatlar mavjudligi, siqilish zonasida og'riq).

B rejimidan foydalanganda qalqonsimon bez saratonining o'ziga xos ultratovush belgilari quyidagilar edi: shaklning notekisligi — 70 holatda (75,2%), gipoexogenlik — 78 (84,4%), chegaralarning notekisligi — 74 (79,4%), konturlarning xiralashishi — 74 (79,4%), exostrukturaning geterogenligi — 80 (86,5%).%) giperexoginlik bilan



Rasm: 1. KEG rejimi. Qalqonsimon bezning o'zgarmagan parenximasi, o'rtacha intensivlikdagi bir hil rang berish, ko'k rang naqshlari aniqlanadi.

25 (26,9%) va 23 (25,0%) mikrokalsifikatsiyalar, 27 (29,0%) gipoexogin maydon mavjudligi. Qalqonsimon bez saratoni bilan og'rigan bemorlarni ultratovush tekshiruvda RDX rejimidan foydalanish shuni ko'rsatdiki, 79 ta holatda (85,1%) qon tomirlarining aralash peri - va intranodulyar vaskulyarizatsiyasi bo'lgan tugunlar mavjud; bundan tashqari. 80 ta holatda (86,5%) tomirlarning notekis assimetrik taqsimlanishi va 78 ta holatda (84,3%) ularning deformatsiyasi kuzatildi.

QB saratonini tashxislash uchun KEG dan foydalanishni baholashda noaniq ma'lumotlar olingan .Xususan, qalqonsimon bezning malign o'smalarida rang naqshining intensivligi va bir xilligi har xil edi (rasm. 2 va 3).

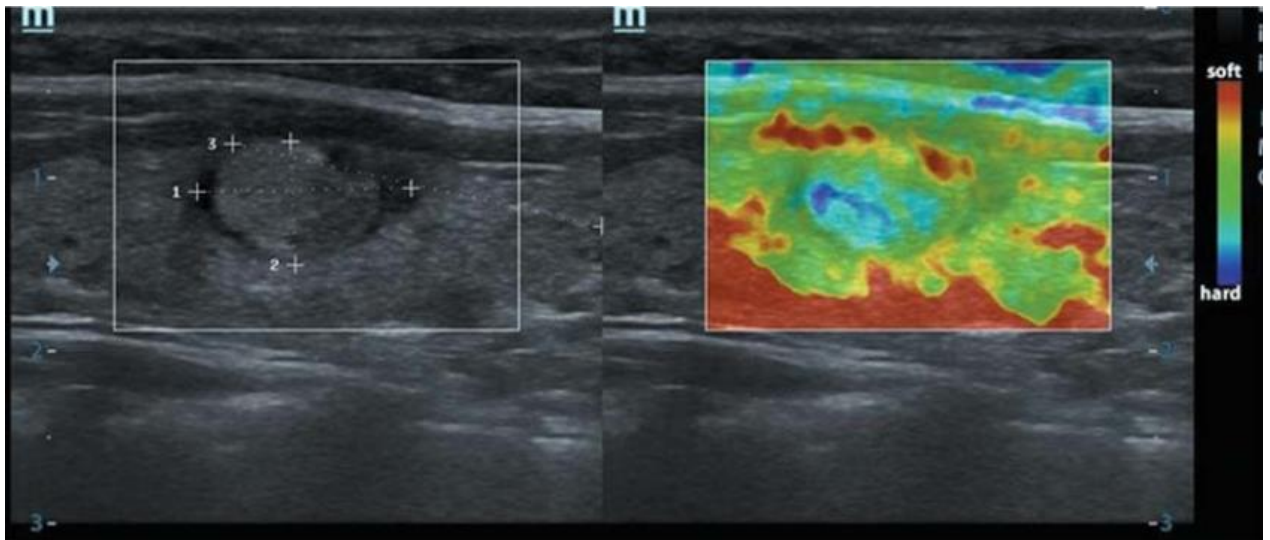
KEG metodologiyasini amalga oshirishda uning quyidagi xususiyatlari aniqlandi, bu noto'g'ri rang naqshini olishga va olingan natijalarni talqin qilishda xatolarga olib kelishi mumkin:

KEG natijalarini talqin qilishning operatorga bog'liqligi;

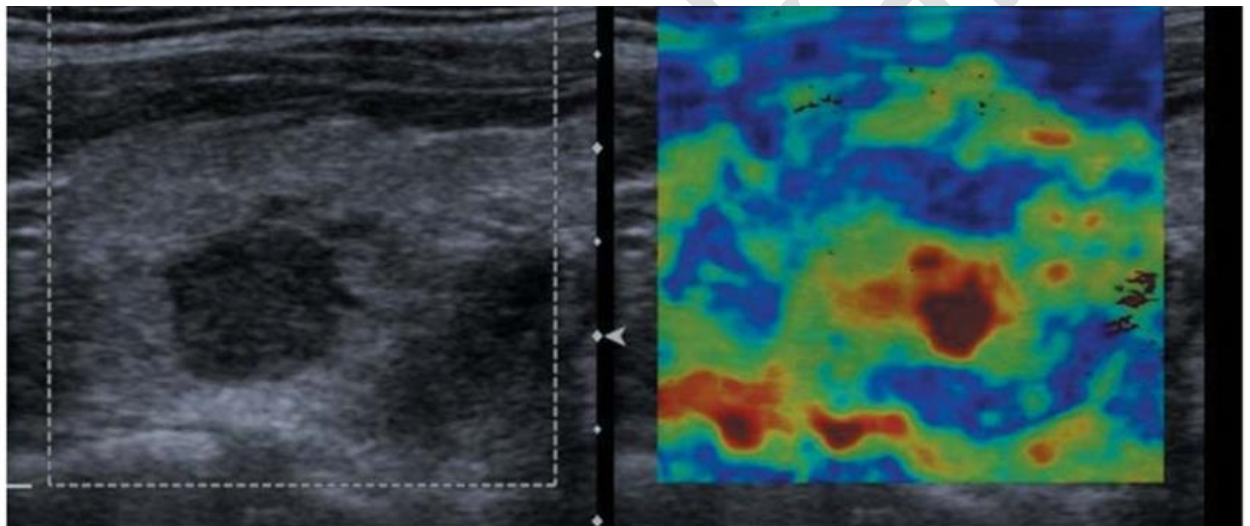
qurilma ishlab chiqaruvchilarida rang naqshlarini yagona standartlashtirishning yo'qligi

Ultratovush;anatomik-konstitutsiyaviy va fiziologik xususiyatlarga ega bo'lgan bemorlarda, xususan, qalqonsimon bez tugunli xosilalarinigning dozali siqilishini amalga oshirishda texnik qiyinchiliklarning paydo bo'lishi. traxeyaning yaqinligi yoki bo'yinning mushak tarkibiy qismining sezilarli qarshiligi bilan, shuningdek tadqiqot davomida noqulaylik va og'riq hissi paydo bo'lishidan shikoyat qilgan bemorlarda;

Saraton kasalligiga chalingan qalqonsimon bezdagi ko'ndalang to'lqin tezligi 3,57 m / s dan oshadi va zichlik nisbati indeksi (elastiklik moduli) 1,56 dan katta qiymatlarni oladi (rasm. 4 va 5). Yaxshi Sifatli tugunli shakllanishlarni o'rganish natijasida QBko'ndalang to'lqin tezligi 3,57 m/s dan kam ekanligi aniqlandi va indeks zichlik nisbati (elastiklik moduli) — 1,56 dan kam (rasm. 6 va 7).



Rasm: 2. Qalqonsimon bezning follikulyar saratoni. Aniq gipoexogin konturli $13 \times 7 \times 12$ mm izoexogen tugun. KEG-da qizg'in rang berish, ko'k rang sxemasi.

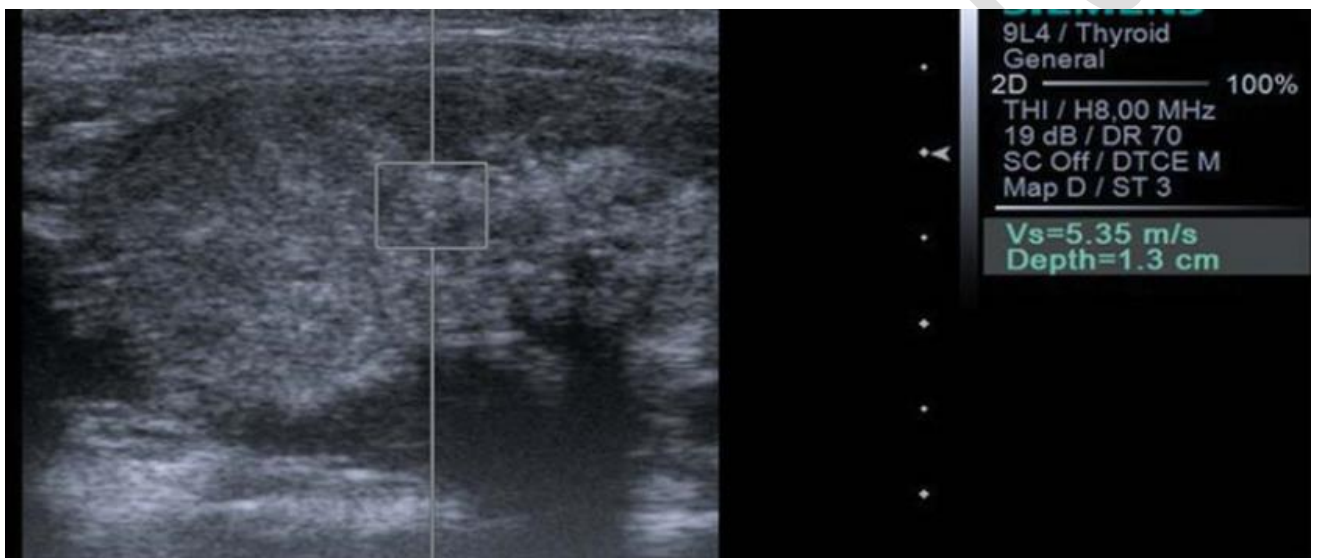


Rasm: 3. Papiller tiroid saratoni Gipoexogin tugun $10 \times 11 \times 10$ mm, aniq kontur bilan. KEG-da intensiv "mozaik" bo'yash.

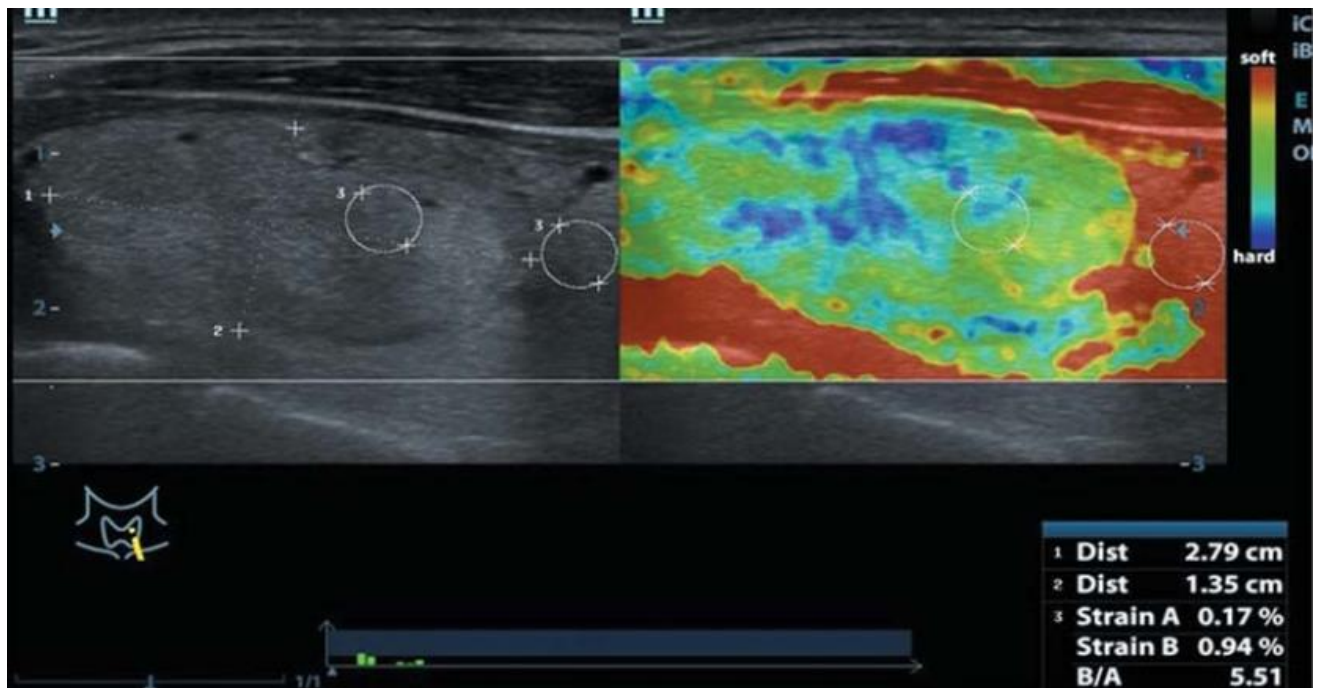
Shunday qilib, qiziqish zonasida qalqonsimon bezning egiluvchanligi ko'rsatkichini baholashda ARFI elastografiyasining samaradorligi KEG bilan taqqoslaganda yuqori bo'ladi. Buning sababi, birinchidan, ARFI-elastografiyadan foydalanish miqdoriy ko'rsatkichlarni olish imkonini beradi, ikkinchidan, bu usul KEG ga qaraganda kamroq operatorga bog'liq.

15,0% hollarda elastometriya texnologiyasidan foydalanish muayyan qiyinchiliklar bilan bog'liq. Qalqonsimon bezning qisman ko'krak qafasida joylashishi qiyinchiliklarni yuzaga keltiradi

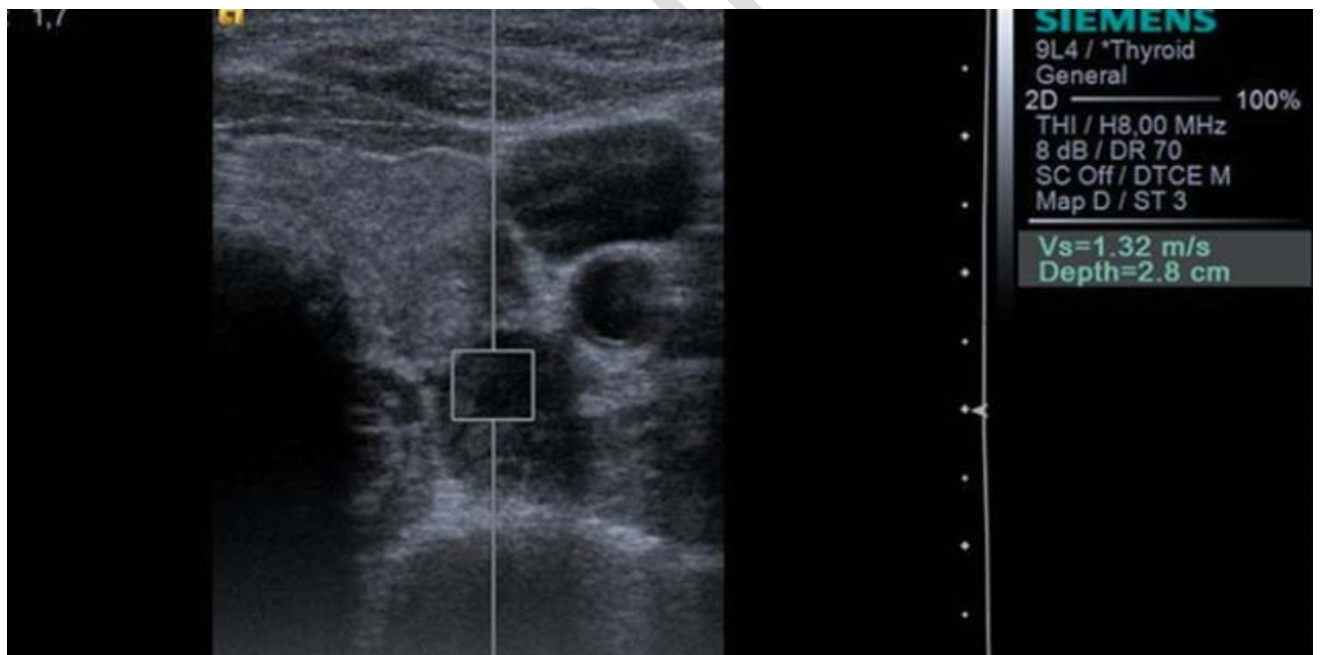
KEG va arfi-elastografiyani birgalikda qo'llash, qalqonsimon bezning nodulyar patologiyalarini differentsial tashxislashda, o'rganilayotgan tugunning ichki tuzilishining bir xilligini baholashga imkon berdi (ichki tuzilishning geterogenligi holatlarning uchdan biridan ko'prog'ida kuzatilgan). Invaziv o'sish chegaralari va perifokal induratsiyaning zo'ravonligi tafsilotlari tufayli o'rganilgan tugunlarning o'lchamlari aniqlandi. Bundan tashqari, seroskal ultratovush yordamida aniqlangan tugunli tuzilmalarning organga mansubligini aniqlash mumkin edi, bu aniq tashxis qo'yish uchun yuqori darajadagi ishonch bilan imkon berdi — PSHJ, intratiroidal joylashgan



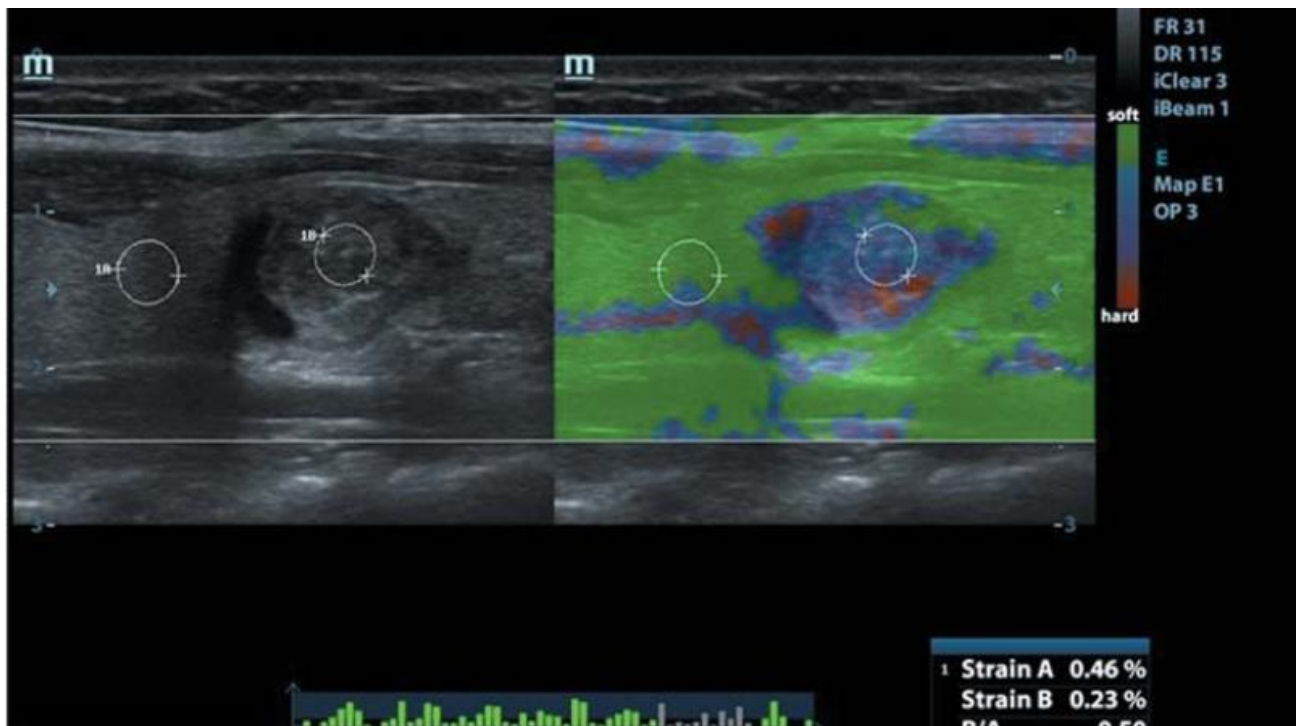
Rasm: 4. Qalqonsimon bezning papiller saratoni. 46×31×39 mm tekis konturli o'rtacha ekogenlikning bir xil bo'lmagan shakllanishi. ultrasonik elastometriya (ARFI) bilan yon to'lqin tezligi 5,35 m/s.



Rasm. 5. Qalqonsimon bezning papiller saratoni. $35 \times 21 \times 29$ mm aniq konturli, bir xil bo'lmagan tuzilmaning izoexogen shakllanishi. ultratovushli elastometriya (strain ratio) bilan $5,51$ m/s.



Rasm: 6. I darajali tugunli kolloid bo'qoq. Chap lobda $15 \times 14 \times 12$ mm tekis konturli, gipoexogenlikning bir xil bo'lmagan shakllanishi aniqlanadi. ultrasonik elastometriya (ARFI) bilan yon to'lqin tezligi $1,32$ m/s



Rasm. 7. I darajali tugunli kolloid bo'qoq. O'nglobda $11 \times 12 \times 10$ mm geterogen strukturaning aniq konturiga ega bo'lgan izoexogen shakllanish aniqlanadi. ultratovushli elastometriya (strain ratio) bilan tugunning elastiklik indeksi 0,50 ni tashkil qiladi.

Shunday qilib, o'tkazilgan tadqiqot shuni ko'rsatdiki, qalqonsimon bez saratonining o'ziga xos ultratovush belgilari quyidagilardan iborat: KEG rejimida bo'yashning mavjudligi ($p < 0,01$); kulrang shkala rejimida va KEG ($p < 0,01$) dan foydalanganda olingan shakllanish hajmining mos p kelmasligi; rang naqshini intensiv bo'yash ($p > 0,05$); tugunning geterogen bo'yalishi ($p > 0,05$).

Tugundagi TEG ning ob'ektiv ma'lumotlariga asoslanib, to'qimalarning qattiqligini miqdoriy jihatdan tavsiflovchi, o'zgartirilgan parenximaning qattiqligining o'zgarmaganlarning o'rtacha ko'rsatkichlaridan og'ishini katta ishonchlilik darajasi bilan baholash mumkin. Arfi-elastografiya rejimida o'smadagi o'rtacha to'lqin tezligi $3,74 \pm 0,17$ m/s, strain ratio indeksi $2,4 \pm 0,84$ ni tashkil etdi.

Operatsiyadan oldingi bosqichda QBR diagnostikasida KEG natijalari boshqa usullari yordamida olingan ma'lumotlarni 12,7%, elastografiya va elastometriyadan kompleks foydalanish esa 34,0% kuzatishlar bilan to'ldirdi.

Xulosalar

Elastografiya operatsiyadan oldingi bosqichda tugunlarning haqiqiy o'lchamlarini aniqlashga imkon beradi, bu operatsiya hajmi va turini aniqlashda katta ahamiyatga ega.

KEG va ARFI-elastografiyasini kompleks qo'llash, qalqonsimon bez tugun patologiyalarini differentsial tashxislashda, har bir usulning "zaif" tomonlarini yo'q qilish tufayli yuqori sezuvchanlik (91,6%) va o'ziga xoslik (88,8%) bilan ajralib turadi.

Qalqonsimon bez tugunli neoplazmalarini kompleks tashxislashda TEG dan foydalanish juda informatsiondir, shuning uchun qalqonsimon bezda malign o'smalar mavjudligiga shubha tug'ilsa, tugunlarning hajmini aniqlab, atrofdagi to'qimalarga o'sma kirib borishini aniqlash kerak.

Adabiyotlar

1. Abdurakhmanovich, K. O., & ugli, G. S. O. (2022). Ultrasonic Diagnosis Methods for Choledocholithiasis. Central Asian Journal Of Medical And Natural Sciences, 3(2), 43-47.
2. Abdurakhmanovich, K. O., & ugli, G. S. O. (2022). Ultrasound Diagnosis of the Norm and Diseases of the Cervix. Central Asian Journal Of Medical And Natural Sciences, 3(2), 58-63.
3. Akbarov S. et al. VALUE OF US AND DOPPLEROMETRY IN CHRONIC PYELONEPHRITIS OF PREGNANT WOMEN //Yangi O'zbekiston talabalari axborotnomasi. – 2023. – T. 1. – №. 2. – C. 26-29.
4. Akhmedov YA, Ataeva SKh, Ametova AS, Bazarova SA, Isakov HKh THE HISTORY OF THE DEVELOPMENT OF RADIATION DIAGNOSTICS. Web of scientist: International scientific research journal. 2021;2:34-42.
5. Akhmedov YA, Rustamov UKh, Shodieva NE, Alieva UZ, Bobomurodov BM Modern Application of Computer Tomography in Urology. Central Asian journal of medical end natural sciences. 2021;2(4):121-125.
6. Alimdjanovich, R.J., Obid , K., Javlanovich, Y.D. and ugli, G.S.O. 2022. Advantages of Ultrasound Diagnosis of Pulmonary Pathology in COVID-19 Compared to Computed Tomography. Central Asian Journal of Medical and Natural Science. 3, 5 (Oct. 2022), 531-546.
7. Amandullaevich A. Y., Abdurakhmanovich K. O. Organization of Modern Examination Methods of Mammary Gland Diseases //Central Asian Journal of Medical and Natural Science. – 2022. – T. 3. – №. 5. – C. 560-569.
8. Ataeva SKh, Ravshanov ZKh, Ametova AS, Yakubov DZh Radiation visualization of chronic joint diseases. Central Asian journal of medical end natural sciences. 2021;2(2):12-17

9. Babajanovich K. Z., Abdurakhmanovich K. O., Javlanovich Y. D. Ultrasound and MSCT as the Next Step in the Evolution of the Examination of Patients with Ventral Hernias //Central Asian Journal of Medical and Natural Science. – 2022. – T. 3. – №. 5. – C. 583-591.
10. Hamidov OA, Diagnostics of injuries of the soft tissue structures of the knee joint and their complications. European research. Moscow. 2020;1(37):33-36.
11. Kadirov J. F. et al. NEUROLOGICAL COMPLICATIONS OF AIDS //Journal of new century innovations. – 2022. – T. 10. – №. 5. – C. 174-180.
12. Khamidov OA, Akhmedov YA, Ataeva SKh, Ametova AS, Karshiev BO Role of Kidney Ultrasound in the Choice of Tactics for Treatment of Acute Renal Failure. Central Asian journal of medical end natural sciences. 2021;2(4):132-134
13. Khamidov OA, Akhmedov YA, Yakubov DZh, Shodieva NE, Tukhtaev TI DIAGNOSTIC POSSIBILITIES OF USES IN POLYKYSTOSIS OF KIDNEYS. Web of scientist: International scientific research journal. 2021;2(8):27-33
14. Khamidov OA, Ataeva SKh, Ametova AS, Yakubov DZh, Khaydarov SS A Case of Ultrasound Diagnosis of Necrotizing Papillitis. Central Asian journal of medical end natural sciences. 2021;2(4):103-107
15. Khamidov OA, Ataeva SKh, Yakubov DZh, Ametova AS, Saytkulova ShR ULTRASOUND EXAMINATION IN THE DIAGNOSIS OF FETAL MACROSOMIA. Web of scientist: International scientific research journal. 2021;2(8):49-54
16. Khamidov OA, Khodzhanov IYu, Mamasoliev BM, Mansurov DSh, Davronov AA, Rakhimov AM The Role of Vascular Pathology in the Development and Progression of Deforming Osteoarthritis of the Joints of the Lower Extremities (Literature Review). Annals of the Romanian Society for Cell Biology, Romania. 2021;1(25):214 – 225
17. Khamidov OA, Mirzakulov MM, Ametova AS, Alieva UZ Multispiral computed tomography for prostate diseases. Central Asian journal of medical end natural sciences. 2021;2(2):9-11
18. Khamidov OA, Normamatov AF, Yakubov DZh, Bazarova SA Respiratory computed tomography. Central Asian journal of medical end natural sciences. 2021;2(2):1-8
19. Khamidov OA, Urozov UB, Shodieva NE, Akhmedov YA Ultrasound diagnosis of urolithiasis. Central Asian journal of medical end natural sciences. 2021;2(2):18-24
20. Khamidov OA, Yakubov DZh, Alieva UZ, Bazarova SA, Mamaruziev ShR Possibilities of Sonography in Differential Diagnostics of Hematuria. Central Asian journal of medical end natural sciences. 2021;2(4):126-131
21. Khamidov OA, Yakubov DZh, Ametova AS, Bazarova SA, Mamatova ShT Application of the Ultrasound Research Method in Otorhinolaryngology and Diseases of the Head and Neck Organs. International Journal of Development and Public Policy. 2021;1(3):33-37

22. Khamidov OA, Yakubov DZh, Ametova AS, Turdumatov ZhA, Mamatov RM Magnetic Resonance Tomography in Diagnostics and Differential Diagnostics of Focal Liver Lesions. *Central Asian journal of medical end natural sciences*. 2021;2(4):115-120
23. Khamidov Obid Abdurakhmanovich, Davranov Ismoil Ibragimovich, Ametova Alie Servetovna. (2023). The Role of Ultrasound and Magnetic Resonance Imaging in the Assessment of Musculo-Tendon Pathologies of the Shoulder Joint. *International Journal of Studies in Natural and Medical Sciences*, 2(4), 36–48. Retrieved from <https://scholarsdigest.org/index.php/ijsnms/article/view/95>
24. Khasanova Diyora Zafarjon kizi, Khamidov Obid Abdurakhmonovich and Juraev Kamoliddin Danabaevich 2023. SYMPHYSIOPATHY AND PREGNANCY. "Conference on Universal Science Research 2023". 1, 2 (Feb. 2023), 55–60.
25. Khudayberdiyevich Z. S. et al. Possibilities and Prospects of Ultrasound Diagnostics in Rheumatology // *Central Asian Journal of Medical and Natural Science*. – 2022. – T. 3. – №. 5. – C. 570-582.
26. Nurmurzayev Z.N.; Suvonov Z.K.; Khimmatov I.Kh. Ultrasound of the Abdominal Cavity. *JTCOS* 2022, 4, 89-97.
27. Obid, K., Servetovna, A. A., & Javlanovich, Y. D. (2022). Diagnosis and Structural Modification Treatment of Osteoarthritis of the Knee. *Central Asian Journal of Medical and Natural Science*, 3(5), 547-559.
28. Rustamov UKh, Shodieva NE, Ametova AS, Alieva UZ, Rabbimova MU US-DIAGNOSTICS FOR INFERTILITY. *Web of scientist: International scientific research journal*. 2021;2(8):55-61
29. Rustamov UKh, Urinboev ShB, Ametova AS Ultrasound diagnostics of ectopic pregnancy. *Central Asian journal of medical end natural sciences*. 2021;2(2):25-28
30. Usarov M.Sh, Otakulov Z.Sh and Rakhmonkulov Sh. H. 2022. Contrast-enhanced ultrasound in the differential diagnosis of focal nodular hyperplasia and hepatocellular liver adenoma. *Journal the Coryphaeus of Science*. 4, 4 (Dec. 2022), 70–79.
31. Yakubov, J., Karimov, B., Gaybullaev, O., and Mirzakulov, M. 2022. Ultrasonic and radiological picture in the combination of chronic venous insufficiency and osteoarthritis of the knee joints. *Academic Research in Educational Sciences*. 5(3), pp.945–956.
32. Yakubov D. Z., Gaybullaev S. O. The diagnostic importance of radiation diagnostic methods in determining the degree of expression of gonarthrosis // *UZBEK JOURNAL OF CASE REPORTS*. – C. 36.
33. Yakubov D.J., Turanov A.R. and Baymuratova A.C. 2022. Possibilities of contrast-enhanced ultrasound tomography in the diagnosis of metastatic liver lesions in patients with cervical cancer. *Journal the Coryphaeus of Science*. 4, 4 (Dec. 2022), 80–88.

34. Yakubov Doniyor Javlanovich, Juraev Kamoliddin Danabaevich, Gaybullaev Sherzod Obid ugli, and Samiev Azamat Ulmas ugli. 2022. "INFLUENCE OF GONARTHROSIS ON THE COURSE AND EFFECTIVENESS OF TREATMENT OF VARICOSE VEINS". *Yosh Tadqiqotchi Jurnal* 1 (4):347-57.
35. Yusufzoda Hosiyat Turon kizi, Khamidov Obid Abdurakhmonovich and Juraev Kamoliddin Danabaevich 2023. DIAGNOSIS OF CHANGES IN PREGNANT WOMEN WITH VULVOVAGINITIS. "Conference on Universal Science Research 2023". 1, 2 (Feb. 2023), 51–55.
36. Ахмедов Якуб Амандуллаевич; Гайбуллаев Шерзод Обид угли; Хамидова Зиёда Абдивахобовна. МРТ В СРАВНЕНИИ С ДИАГНОСТИЧЕСКОЙ АРТРОСКОПИЕЙ КОЛЕННОГО СУСТАВА ДЛЯ ОЦЕНКИ РАЗРЫВОВ МЕНИСКА. *Tadqiqotlar* 2023, 7, 105-115.
37. Гайбуллаев Ш., Усаров М., Далерова М. НОРМАЛЬНЫЕ УЛЬТРАЗВУКОВЫЕ РАЗМЕРЫ ЖЕЛЧНОГО ПУЗЫРЯ И ОБЩЕГО ЖЕЛЧНОГО ПРОТОКА У НОВОРОЖДЕННЫХ // *Involta Scientific Journal*. – 2023. – Т. 2. – №. 1. – С. 142-148.
38. Кадиров Ж. Ф. и др. МАГНИТНО-РЕЗОНАНСНАЯ ТОМОГРАФИЧЕСКАЯ ОЦЕНКА ПОРАЖЕНИЙ ЦЕНТРАЛЬНОЙ НЕРВНОЙ СИСТЕМЫ У БОЛЬНЫХ, ИНФИЦИРОВАННЫХ ВИРУСОМ ИММУНОДЕФИЦИТА ЧЕЛОВЕКА // *Journal of new century innovations*. – 2022. – Т. 10. – №. 5. – С. 157-173.
39. Нурмурзаев, З. Н., Жураев, К. Д., & Гайбуллаев, Ш. О. (2023). ТОНКОИГОЛЬНАЯ АСПИРАЦИОННАЯ ЦИТОЛОГИЯ ПОД УЛЬТРАЗВУКОВЫМ КОНТРОЛЕМ В ДИАГНОСТИКЕ ЗАБРЮШИННЫХ ОБРАЗОВАНИЙ: ИССЛЕДОВАНИЕ 85 СЛУЧАЕВ. *Academic Research in Educational Sciences*, 4(4), 126–133.
40. Хамидов, О., Гайбуллаев, Ш. и Давранов, И. 2023. СРАВНЕНИЕ РЕЗУЛЬТАТОВ УЗИ И МРТ В ДИАГНОСТИКЕ ПОВРЕЖДЕНИЙ МЕНИСКА КОЛЕННОГО СУСТАВА. *Евразийский журнал медицинских и естественных наук*. 3, 4 (апр. 2023), 176–183.
41. Хамидов О. А., Гайбуллаев Ш. О., Хакимов М. Б. ОБЗОР МЕТОДОВ ОБРАБОТКИ ИЗОБРАЖЕНИЙ ДЛЯ ДИАГНОСТИКИ ПАТОЛОГИИ ГОЛОВНОГО МОЗГА: ПРОБЛЕМЫ И ВОЗМОЖНОСТИ // *Journal of new century innovations*. – 2022. – Т. 10. – №. 5. – С. 181-195.
42. Хамидов О. А., Гайбуллаев Ш. О., Хомидова Д. Д. РОЛЬ УЛЬТРАЗВУКА И МАГНИТНО-РЕЗОНАНСНОЙ ТОМОГРАФИИ В ОЦЕНКЕ МЫШЕЧНО-СУХОЖИЛЬНЫХ ПАТОЛОГИЙ ПЛЕЧЕВОГО СУСТАВА // *Uzbek Scholar Journal*. – 2023. – Т. 12. – С. 125-136.
43. Хамидов О.А. Оптимизация лучевой диагностики повреждений мягкотканых структур коленного сустава и их осложнений, *Американский журнал медицины и медицинских наук*. 2020;10 (11):881-884. (In Russ.)

44. Хамидов, О. А., Жураев, К. Д., & Муминова, Ш. М. (2023). СОНОГРАФИЧЕСКАЯ ДИАГНОСТИКА ПНЕВМОТОРАКСА. *World scientific research journal*, 12(1), 51-59.
45. Ходжибеков М.Х., Хамидов О.А. Обоснование ультразвуковой диагностики повреждений внутрисуставных структур коленного сустава и их осложнений. 2020;3(31):526-529. (In Russ.)
46. Юсуфзода Х. и др. ОПТИМАЛЬНЫЕ МЕТОДЫ ДИАГНОСТИКИ СИНДРОМА МИРИЗЗИ //Yangi O'zbekiston talabalari axborotnomasi. – 2023. – Т. 1. – №. 2. – С. 21-25.
47. Якубов Д. Д., Давранов И. И., Шодикулова П. Ш. ХАРАКТЕРИСТИКИ МСКТ И ДИАГНОСТИЧЕСКАЯ ЦЕННОСТЬ COVID-19 ПРИ БЕРЕМЕННОСТИ //Journal of new century innovations. – 2023. – Т. 22. – №. 1. – С. 165-176.
48. Якубов Д. Ж., Гайбуллаев Ш. О. Влияние посттравматической хондропатии на функциональное состояние коленных суставов у спортсменов. *Uzbek journal of case reports*. 2022; 2 (1): 36-40. – 2022.
49. угли, Н. З. Н., Шухратович, У. М., Хуршедовна, А. С. and Фаёзович, В. Ф. (2023) “Роль Ультразвука В Оценке Повреждения Мениска”, *Central Asian Journal of Medical and Natural Science*, 4(2), pp. 588-595. doi: 10.17605/OSF.IO/M5HZP.
50. Жавланович, Я. Д., Амандуллаевич, А. Я., Зафаржонович, У. З., & Павловна, К. Т. (2023). Мультипараметрическая МРТ В Диагностике Рака Предстательной Железы. *Central Asian Journal of Medical and Natural Science*, 4(2), 577-587. <https://doi.org/10.17605/OSF.IO/MQDHP>
51. угли, А.С.Н., Хамидович, Р.Ш. and Данабаевич, Ж.К. 2023. Кость При Остеоартрите: Визуализация. *Central Asian Journal of Medical and Natural Science*. 4, 3 (Jun. 2023), 895-905.
52. Z., Umarmkulov Z., Khakimov M. B., and Suvonov Z. K. 2023. “Ultrasound Diagnostics and Diagnostics of Focal Liquid Lesions of the Liver”. *Central Asian Journal of Medical and Natural Science* 4 (3), 986-94. <https://cajmns.centralasianstudies.org/index.php/CAJMNS/article/view/1607>
53. N., Nurmurazayev Z., Abduqodirov Kh. M., and Akobirov M. T. 2023. “Transabdominal Ultrasound for Inflammatory and Tumoral Diseases Intestine: New Possibilities in Oral Contrasting With Polyethylene Glycol”. *Central Asian Journal of Medical and Natural Science* 4 (3), 973-85. <https://cajmns.centralasianstudies.org/index.php/CAJMNS/article/view/1606>
54. S., Usarov M., Turanov A. R., and Soqiev S. A. 2023. “Modern Clinical Capabilities of Minimally Invasive Manipulations under Ultrasound Control”. *Central Asian Journal of Medical and Natural Science* 4 (3), 956-66. <https://cajmns.centralasianstudies.org/index.php/CAJMNS/article/view/1604>

- 55.I., Davranov I., and Uteniyazova G. J. 2023. "Koronavirus Diagnostikasida O'pkani Ktsi: Qachon, Nima Uchun, Qanday Amalga Oshiriladi?". Central Asian Journal of Medical and Natural Science 4 (3), 947-55. <https://cajmns.centralasianstudies.org/index.php/CAJMNS/article/view/1602>
- 56.P., Kim T., and Baymuratova A. C. 2023. "Fast Technology for Ultrasonic Diagnosis of Acute Coleculosis Cholecystitis". Central Asian Journal of Medical and Natural Science 4 (3), 940-46. <https://cajmns.centralasianstudies.org/index.php/CAJMNS/article/view/1601>
- 57.A., Khamidov O., and Shodmanov F. J. 2023. "Computed Tomography and Magnetic Resonance Imaging Play an Important Role in Determining the Local Degree of Spread of Malignant Tumors in the Organ of Hearing". Central Asian Journal of Medical and Natural Science 4 (3), 929-39. <https://cajmns.centralasianstudies.org/index.php/CAJMNS/article/view/1600>
- 58.O., Gaybullaev S., Fayzullayev S. A., and Khamrakulov J. D. 2023. "Cholangiocellular Cancer Topical Issues of Modern Ultrasound Diagnosis". Central Asian Journal of Medical and Natural Science 4 (3), 921-28. <https://cajmns.centralasianstudies.org/index.php/CAJMNS/article/view/1599>
- 59.угли, Химматов Ислом Хайрулло, Сувонов Зуфар Кахрамон угли, and Умаркулов Забур Зафаржонович. 2023. "Визуализация Множественной Миеломы". Central Asian Journal of Medical and Natural Science 4 (3), 906-16. <https://cajmns.centralasianstudies.org/index.php/CAJMNS/article/view/1597>
- 60.Gaybullaev S. O., Fayzullayev S. A., Khamrakulov J. D. Cholangiocellular Cancer Topical Issues of Modern Ultrasound Diagnosis //Central Asian Journal of Medical and Natural Science. – 2023. – Т. 4. – №. 3. – С. 921-928.
- 61.Alimdjanovich, Rizayev Jasur, et al. "Start of Telemedicine in Uzbekistan. Technological Availability." Advances in Information Communication Technology and Computing: Proceedings of AICTC 2022. Singapore: Springer Nature Singapore, 2023. 35-41.
- 62.Khamidov O. A., Shodmanov F. J. Computed Tomography and Magnetic Resonance Imaging Play an Important Role in Determining the Local Degree of Spread of Malignant Tumors in the Organ of Hearing //Central Asian Journal of Medical and Natural Science. – 2023. – Т. 4. – №. 3. – С. 929-939.
- 63.Khamidov Obid Abdurakhmanovich, Gaybullaev Sherzod Obid ugli 2023. COMPARATIVE ANALYSIS OF CLINICAL AND VISUAL CHARACTERISTICS OF OSTEOMALACIA AND SPONDYLOARTHRITIS. Science and innovation. 3, 4 (May 2023), 22–35.
- 64.Khamidov Obid Abdurakhmanovich, Gaybullaev Sherzod Obid ugli 2023. COMPARATIVE ANALYSIS OF CLINICAL AND VISUAL

- CHARACTERISTICS OF OSTEOMALACIA AND SPONDYLOARTHRITIS. *Science and innovation*. 3, 4 (May 2023), 22–35.
65. Abdurakhmanovich, K. O. (2023). Options for diagnosing polycystic kidney disease. *Innovation Scholar*, 10(1), 32-41.
66. Abdurakhmanovich, K. O., & Javlanovich, Y. D. (2023). COMPARISON OF MRI WITH DIAGNOSTIC KNEE ARTHROSCOPY FOR EVALUATING MENISCAL TEARS. *Zeta Repository*, 4(04), 10-18.
67. Yakubov, D. J., & Pirimov, U. N. (2023). Vergleich der Ergebnisse von Ultraschall und MRT bei der Diagnose von Schäden am Meniskus des Kniegelenks. *New Central Asian Science Journal*, 6(5), 3-11.
68. Khamidov Obid Abdurakhmanovich and Gaybullaev Sherzod Obid ugli 2023. Telemedicine in oncology. *Science and innovation*. 3, 4 (Aug. 2023), 36–44.
69. Khamidov Obid Abdurakhmanovich, Gaybullaev Sherzod Obid ugli and Yakubov Doniyor Jhavlanovich 2023. Переход от мифа к реальности в электронном здравоохранении. *Boffin Academy*. 1, 1 (Sep. 2023), 100–114.
70. Gaybullaev Sh.O., Djurabekova A. T. and Khamidov O. A. 2023. MAGNETIC RESONANCE IMAGRAPHY AS A PREDICTION TOOL FOR ENCEPHALITIS IN CHILDREN. *Boffin Academy*. 1, 1 (Oct. 2023), 259–270.
71. Khamidov O. A. and Dalerova M.F. 2023. The role of the regional telemedicine center in the provision of medical care. *Science and innovation*. 3, 5 (Nov. 2023), 160–171.
72. Yakubov D.J. and Mirkhakimova F.M. 2023. Cerebral edema - possibilities of magnetic resonance imaging. *Journal the Coryphaeus of Science*. 5, 5 (Nov. 2023), 226–236.