

## NEW METHODS POSSIBILITY OF VIDEO LAPAROSCOPY IN DIAGNOSIS AND TREATMENT OF ACUTE INTESTINAL OBSTRUCTION

*Shonazarov Iskandar Shonazarovich., Adizov Faridun Ergashqulovich*

*Samarkand branch of the Republican Scientific Center for Emergency Medical Care, Samarkand State Medical University, Uzbekistan.*

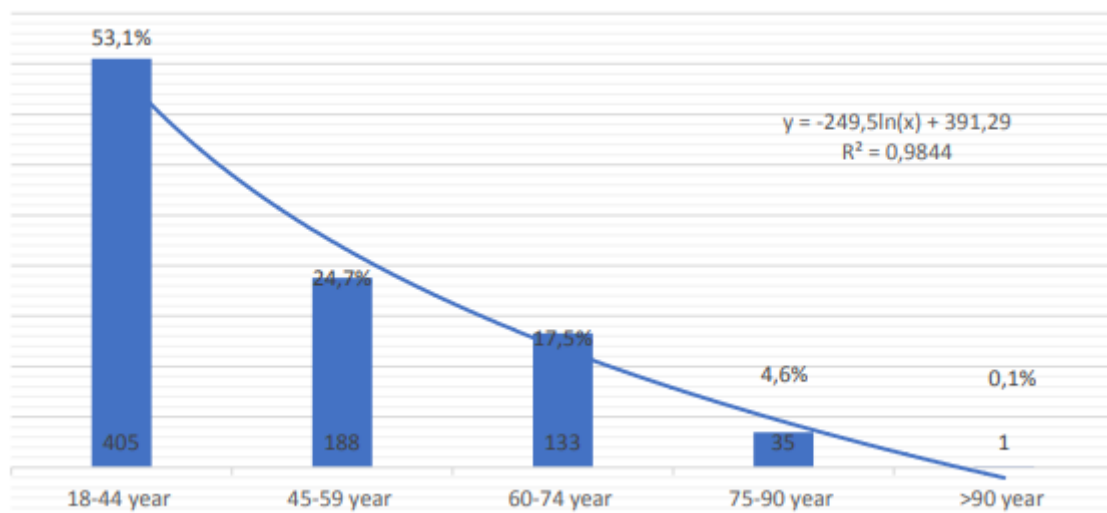
**Relevance.** In recent years, with the growth of the population, the number and scope of various operations in the abdominal organs are increasing, which in turn is progressing in the number of patients with various types of acute intestinal obstruction (AIO). It is adhesive disease that is the main cause of intestinal obstruction in developed countries, and in developing countries, the proportion of AIO is approximately on the same level as strangulated hernia in the structure of the etiology of this disease [1, 2, 14]. The main causes of AIO (more than 90% of cases) are adhesions, ventral hernias and neoplasms [13]. In particular, up to 70% of cases of small bowel AIO occur with adhesions [11], and can also develop with hernias and tumors of the abdominal organs [5]. The cause of colonic obstruction in up to 60% of cases is obstruction of the intestine by a neoplasm [6], in 30% of cases - intestinal volvulus and diverticulosis, as well as other pathologies of the abdominal cavity [9, 11, 13]. The risk of adhesive ileus is highest after colorectal, oncological, gynecological or pediatric operations [6, 14]. For example, after colectomy in the next 3 years, every tenth patient develops at least one episode of AIO [7, 10]. After abdominal operations in children, repeated operations for adhesive AIO are performed in 4.2–12.6% of patients, and after operations for colon tumors - in 3.2% of cases [4, 8, 13]. Along with high morbidity rates, AIO is also distinguished by alarming mortality rates of the order of 9–13%, and in severe advanced cases it can reach 50–70%. Although in recent years there has been a decrease in the level of mortality, nevertheless, according to this indicator, AIO still occupies a leading place among all acute urgent conditions in abdominal surgery [3, 5, 9]. After any abdominal surgery, the patient remains at risk of developing adhesive AIO for life, however, this complication most often manifests itself during the first 2 years after the intervention, and repeated episodes can be observed at any period of the life of the operated patient [3, 5], but still the frequency recurrences of AIO remains higher in young patients [10, 12].

**Purpose of the study:** Optimization of diagnostic and surgical tactics in the treatment of patients with AIO.

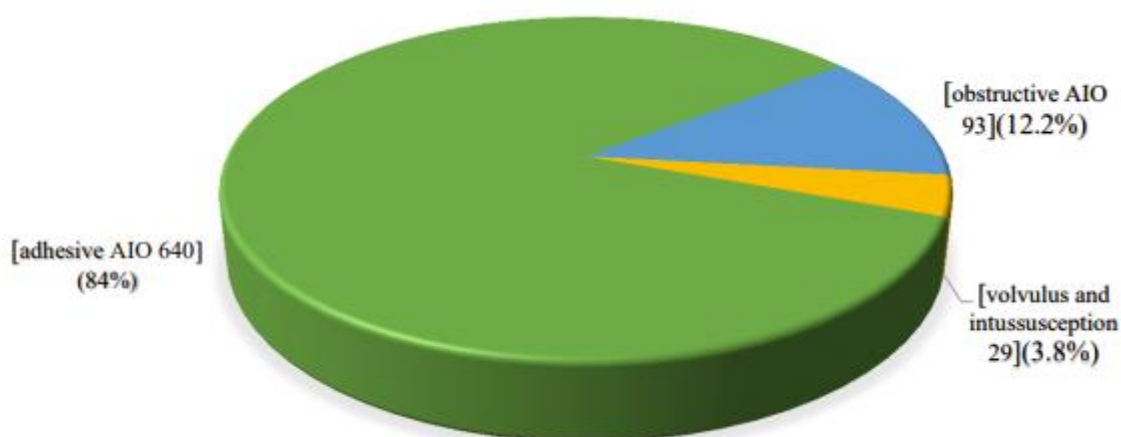
**Material and research methods.** The foundation of the work was the results of examination and treatment of more than 762 patients with AIO operated on in the Samarkand branch of the RRCEM for the period from 2010 to 2019. The mean age of the patients was  $45.8 \pm 18.1$  years with a range of 16 to 90 years. Our observations

show that the incidence of AIO is inversely proportional to age: more than half (53.1%) of patients were at a young age, middle-aged persons accounted for a quarter (24.7%) of all patients, and even fewer were elderly and senile patients. — 17.5 and 4.6%, respectively. And only 1 (0.1%) patient was aged 90 years (Fig. 1).

Pic. 1. Distribution of patients with AIO by age.



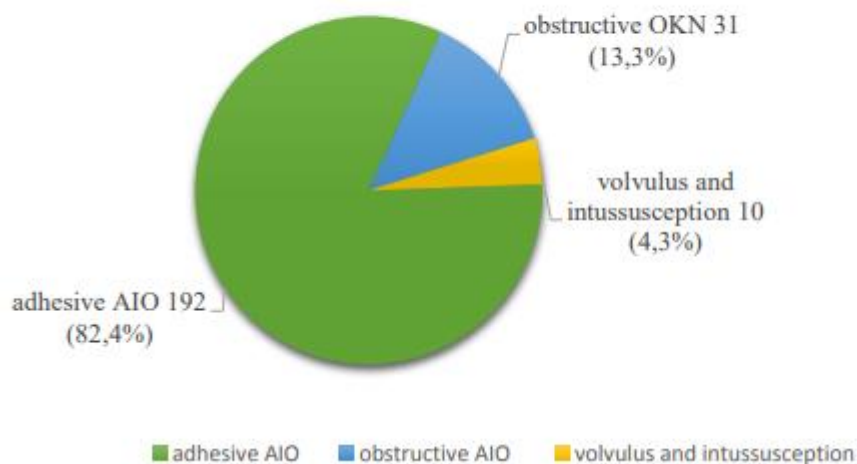
In the structure of AIO, adhesive intestinal obstruction absolutely prevailed, which was diagnosed in 640 (84%) patients. Obstructive AIO was much less common, in 93 (12.2%) patients, as well as dolichosigmoid torsion and various forms of invagination (in 29 (3.8%) cases) (Fig. 2.). Of the total number of operated patients (n=762), 529 (69.4%) patients underwent primary open interventions. In 233 (30.6%) cases, surgery was started with the use of laparoscopic technique, including 192 (25.2%) patients with adhesive intestinal obstruction, 31 (4.1%) with obstructive AIO and 10 (1.3%) - with volvulus and invagination.



Pic. 2. Etiological structure of AIO (n=762).

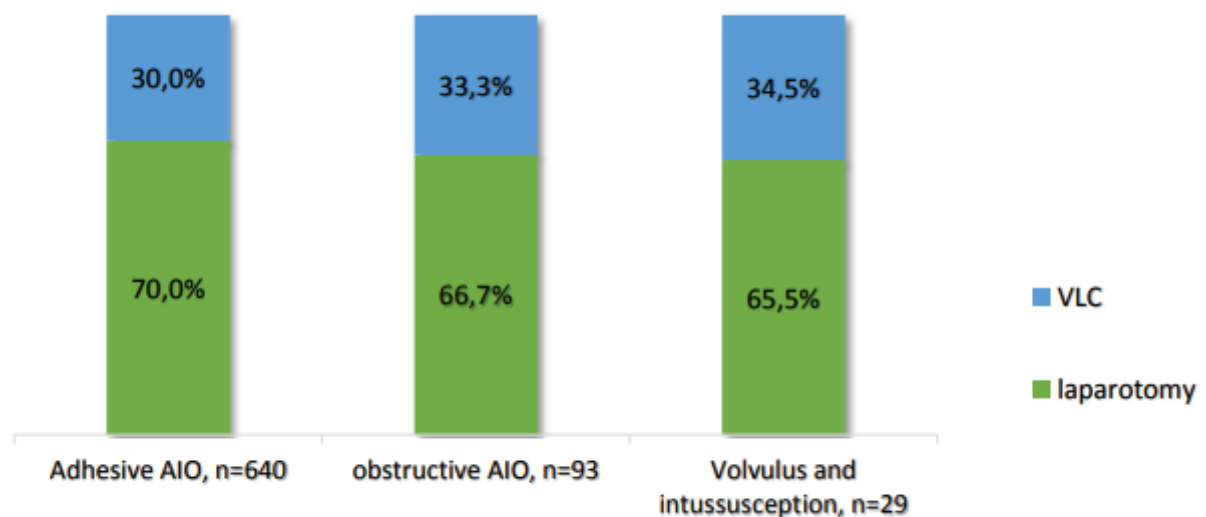
In the etiological structure, operations performed for adhesive intestinal obstruction absolutely prevailed - they were performed in 192 (82.4%) patients, laparoscopic

operations were performed much less frequently in patients with obstructive AIO (31; 13.3%) and for volvulus and invagination of the intestine (10; 4.3%) (Fig. 3), which, by and large, reflects the general structure of the causes of AIO, for which patients were subjected to surgical interventions.



Pic. 3. Types of AIOs for which VLS was performed, n=132.

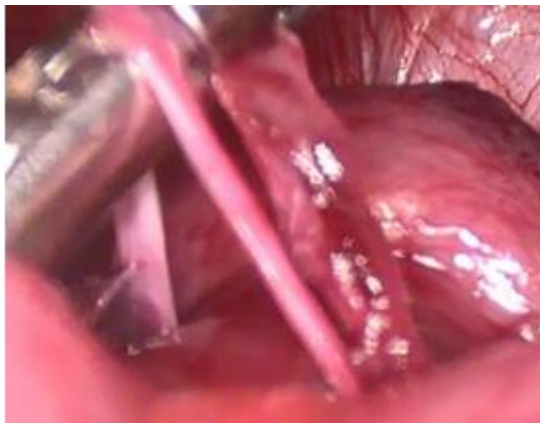
In all etiological forms of AIO, the proportion of videolaparoscopic interventions (VLS) was approximately the same and amounted to 30-33% (Fig. 4.).



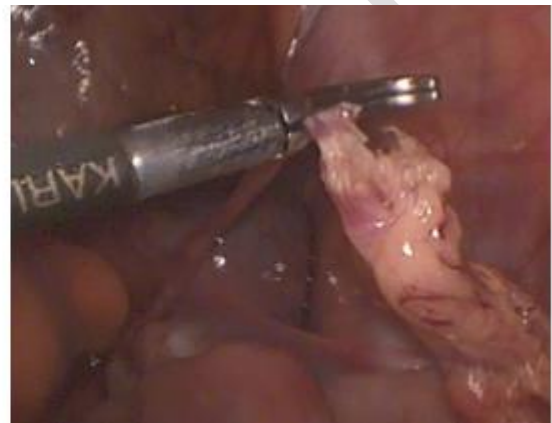Pic. 4. Share of VLS interventions in various forms of AIO, n=762.

At the same time, the share of VLS operations in patients with intestinal obstruction has increased significantly over the past few years, reaching from 8% in the first

year of the introduction of this technology in 2010 to 66% in 2019. As is known, this category of patients with AIO presents a high risk of intraoperative and postoperative complications, especially when laparoscopy is used. Results and discussions. Infringement by a cord (strand) is characterized by localization of the level of obstruction within the ileum or, less commonly, in the middle section of the small intestine. Detailed laparoscopic revision allows visualization of the rods themselves (fibrous adhesive bands), which are often twisted. As a rule, one of the ends of the rod is fixed to the parietal peritoneum, the other - to the intestine or its mesentery. In such cases, laparoscopic surgery was reduced to the release of the extrusion. It was followed along its entire length, isolated with a dissector (Fig. 5.) and cut with scissors close to the intestinal wall, usually after bipolar or monopolar coagulation (Fig. 6.). If there is a long rod, it is necessary to cut it all the way. This is necessary to prevent new adhesions in the postoperative period.

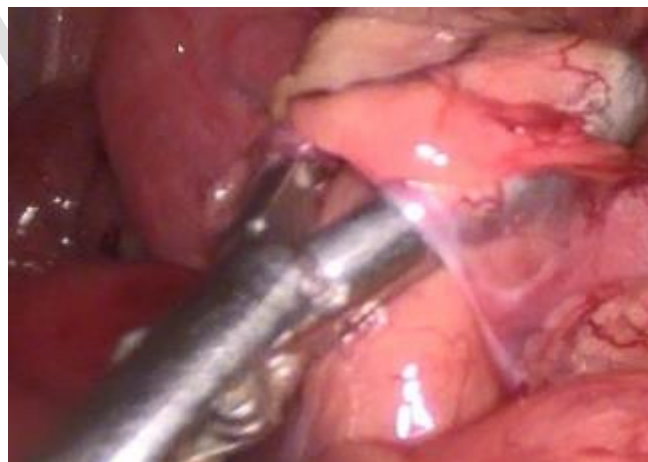

Pic. 5. Extraction of the extrusion.



Pic. 6. Strand electrocoagulation.

Infringement in the window is rarely accompanied by significant microcirculation disorders. Therefore, it is necessary to perform a thorough revision of the intestinal infringement zone with an assessment of the condition of the intestinal and omental loops that form the window, the loops incarcerated in it, as well as the short, no more than 1 cm, adhesion that causes obstruction (Pic. 7.).



Pic. 7. Revision of the infringing window zone.

After the adhesion is isolated with a dissector along its entire circumference, it is necessary to carefully perform its bipolar electrocoagulation and cut with scissors. When treating short adhesions, due to the proximity of the intestinal wall, the use of monopolar coagulation is dangerous. After the release of the restrained bowel loop, a detailed revision of the anatomical formations in the area of the dissected commissure is completed. Operations for adhesive intestinal obstruction, as mentioned above, were performed in 640 patients, of which 448 (70.0%) patients underwent primary laparotomy, 192 (30.0%) - VLS. Videolaparoscopic operations were tried to be performed in persons who had previously undergone no more than 2 abdominal operations, while in the group of patients subjected to primary wide laparotomy (n=448), the number of patients who had a history of more than 2 entries into the abdominal cavity was 58 (12.9%) people, including 17 (3.8%) patients, were admitted with a clinic of adhesive intestinal obstruction after 4 or more abdominal interventions. The results of our study show that the use of laparoscopic access in the surgical treatment of adhesive AIO improves the immediate outcomes of the operation, reduces the frequency of postoperative complications, and reduces the duration of inpatient treatment, especially in patients with single adhesions. We have demonstrated that the selection of patients for laparoscopic interventions, taking into account the number and nature of previous laparotomic operations, is one of the important factors that determine the conversion rate and the incidence of iatrogenic complications. There are numerous observations of specialists indicating that surgical and infectious damage to the peritoneum are considered important risk factors involved in the pathogenesis of adhesion formation and adhesive intestinal obstruction. It was revealed that in 93% of patients who had previously undergone laparotomy, subsequently an adhesive process develops in the abdominal cavity and its severity directly depends on the volume of the surgical intervention.

**Conclusions:** After VLS adhesiolysis, compared with primary laparotomy, there are significantly fewer early postoperative complications (13.0% vs. 43.5%). The use of VLS of adhesiolysis in patients with adhesive AIO helps to reduce the duration of inpatient treatment from  $9.31 \pm 3.31$  to  $5.94 \pm 1.78$  bed-days, and overall mortality from 4.9 to 2.6%.

#### Reference:

1. Абдуллаев С. А. и др. ПРОГНОЗИРОВАНИЕ ТЯЖЕСТИ ТРАВМЫ И ИСХОДА ЛЕЧЕНИЯ ПОСТРАДАВШИХ С СОЧЕТАННОЙ ТРАВМОЙ ГРУДИ И ЖИВОТА //Скорая медицинская помощь. – 2003. – Т. 4. – №. 4. – С. 19-20.
2. Абдуллаев С. А. и др. КЛАССИФИКАЦИЯ СОЧЕТАННОЙ ТРАВМЫ ГРУДИ И ЖИВОТА //Скорая медицинская помощь. – 2003. – Т. 4. – №. 4. – С. 18-18.

3. Юлдашев Ш. С. и др. Болада ёт жисм таъсирида ?изилунгач перфорациям //Вестник экстренной медицины. – 2016. – №. 4. – С. 69-71.
4. Шоназаров И. и др. Наш опыт диагностики и лечения повреждений двенадцатиперстной кишки при сочетанной абдоминальной травме //Журнал проблемы биологии и медицины. – 2017. – №. 3 (96). – С. 122-125.
5. Рузиев П. Н. и др. Результаты лечения тромбоза мезентериальных сосудов //Роль больниц скорой помощи и научно исследовательских институтов в снижении предотвратимой смертности среди населения. – 2018. – С. 190-191.
6. Ачилов М. Т. и др. Панкреатодуоденальная резекция-методика физиологической реконструкции //Достижения науки и образования. – 2020. – №. 6 (60). – С. 38-42.
7. Ачилов М. Т. и др. Ручной колоанальный или аппаратный колоректальный анастомоз //Достижения науки и образования. – 2020. – №. 6 (60). – С. 43-44.
8. Ачилов М. Т. и др. Диагностика и хирургическая коррекция синдрома Мириizzi //Re-health journal. – 2020. – №. 2-2 (6). – С. 111-113.
9. Shonazarov I. et al. Analysis of the results of surgical tactics and treatment in patients with acute necrotic pancreatitis //European Journal of Molecular & Clinical Medicine. – 2020. – Т. 7. – №. 3. – С. 3130-3135.
10. Shonazarov I. et al. Diagnosis and treatment of adhesive small bowel obstruction with using laparoscopic method //European Journal of Molecular & Clinical Medicine. – 2020. – Т. 7. – №. 3. – С. 3192-3198.
11. Abdullaev S. et al. Problems of Diagnostics, Prevention and Surgical Tactics of Treatment of Adhesive-Intestinal Obstruction //Annals of the Romanian Society for Cell Biology. – 2021. – С. 2289-2294.
12. Temirovich A. M. et al. Prevention and treatment of intraabdominal hypertension in patients with peritonitis //Вестник науки и образования. – 2021. – №. 3-2 (106). – С. 75-79.
13. Тухтаев Б. Х. и др. Тактика лечения пищеводно-желудочных кровотечений у больных с синдромом портальной гипертензии //Достижения науки и образования. – 2020. – №. 1 (55). – С. 79-82.
14. Akhmedov S. K. et al. Значение раннего энтерального питания у больных с синдромом интраабдоминальной гипертензии при тяжелом остром панкреатите //Инновационное развитие: потенциал науки и современного образования. – 2020. – С. 274-276.
15. Камолидинов С. А. и др. Лапароскопическая диагностика и лечение спаечной кишечной непроходимости //World science: problems and innovations. – 2020. – С. 270-275.
16. Облакулов З. Т. и др. Видеолапароскопическое лечение острой спаечной кишечной непроходимости //Достижения науки и образования. – 2020. – №. 1 (55). – С. 70-73.

17. Шоназаров И. Ш. Пути оптимизации диагностики, лечения и прогноза острой спаечной тонкокишечной непроходимости : дис. – Ташкент, 2008.
18. Ачилов М. Т. и др. ДИАГНОСТИЧЕСКИЕ ОСОБЕННОСТИ И МЕТОДЫ ХИРУРГИЧЕСКОЙ ТАКТИКИ БИЛИАРНОГО ИЛЕУСА //ЖУРНАЛ БИОМЕДИЦИНЫ И ПРАКТИКИ. – 2021. – Т. 6. – №. 1.
19. Thompson B. J., Sherman R. A. Comprehensive Review of Biliary Peritonitis //Topics in companion animal medicine. – 2021. – Т. 44. – С. 100532.
20. Мустафакулов И. Б. и др. СИНДРОМ ВНУТРИБРЮШНОЙ ГИПЕРТЕНЗИИ ПРИ СОЧЕТАННЫХ АБДОМИНАЛЬНЫХ ТРАВМАХ //SCIENTIFIC APPROACH TO THE MODERN EDUCATION SYSTEM. – 2023. – Т. 2. – №. 14. – С. 175-182.
21. Шоназаров И. Ш. и др. ЧРЕСДРЕНАЖНАЯ САНАЦИЯ БИЛИАРНОГО ТРАКТА В ПРОФИЛАКТИКЕ И ЛЕЧЕНИИ ХОЛАНГИОГЕННЫХ АБЦЕСОВ ПЕЧЕНИ //Finland International Scientific Journal of Education, Social Science & Humanities. – 2023. – Т. 11. – №. 1. – С. 807-816.
22. Шоназаров И. Ш. и др. Этапное лечение острого холангита с предварительной декомпрессией желчных протоков //Finland International Scientific Journal of Education, Social Science & Humanities. – 2023. – Т. 11. – №. 1. – С. 817-824.
23. Шоназаров И. Ш., Ачилов М. Т. НОВЫЕ МЕТОДЫ И ДИАГНОСТИКИ ЛАПАРОСКОПИЧЕСКОГО ЛЕЧЕНИЯ КИШЕЧНОЙ НЕПРОХОДИМОСТИ //Research Focus. – 2023. – Т. 2. – №. 11. – С. 148-153.
24. Ачилов М. Т. и др. ПАНКРЕАТОДУОДЕНАЛ РЕЗЕКЦИЯ ОПЕРАЦИЯСИНИНГ ТУРЛАРИ ВА АСОРАТЛАРИ //Research Focus. – 2023. – Т. 2. – №. 11. – С. 110-118.
25. Шоназаров И. Ш. и др. МИНИИНВАЗИВНЫЕ ВМЕШАТЕЛЬСТВА В ЛЕЧЕНИИ ВНУТРИБРЮШНЫХ ЖЕЛЧЕИСТЕЧЕНИЙ ПОСЛЕ ХОЛЕЦИСТЭКТОМИИ //Вестник экстренной медицины. – 2023. – Т. 16. – №. 1. – С. 26-29.
26. Шоназаров И. Ш., Адизов Ф. Э. У. ОПТИМИЗАЦИЯ СОВРЕМЕННЫХ ЛЕЧЕНИЙ ОСТРОЙ ТОНКОЙ КИШЕЧНОЙ НЕПРОХОДИМОСТИ //Research Focus. – 2023. – Т. 2. – №. 3. – С. 227-235.
27. Shonazarovich S. I. et al. ХОЛЕЦИСТЭКТОМИЯ ДАН КЕЙИНГИ АСОРАТЛАРНИ КОРРЕКЦИЯСИДА ДИАПЕВТИК ВА РЕНТГЕНЭНДОБИЛИАР АРАЛАШУВЛАРНИ ?ЎЛЛАШ //JOURNAL OF BIOMEDICINE AND PRACTICE. – 2022. – Т. 7. – №. 6.
28. Shonazarovich S. I. et al. ЎТ ТОШ КАСАЛЛИГИ САБАБЛИ ЎТКАЗИЛГАН ОПЕРАЦИЯ ДАН КЕЙИНГИ САФРОЛИ

- ПЕРИТОНИТНИ ДАВОЛАШДА МИНИИНВАЗИВ  
УСУЛЛАРИНИНГ КЛИНИК САМАРАДОРЛИГИ //JOURNAL OF  
BIOMEDICINE AND PRACTICE. – 2022. – Т. 7. – №. 6.
29. Рузиев П. Н. и др. Опыт консервативного лечения повреждения селезенки при закрытой травме живота //Скорая медицинская помощь-2022. – 2022. – С. 109-110.
30. Kurbonov N. A. et al. MANAGEMENT OF THE MIRIZZI SYNDROME AND THE SURGICAL IMPLICATIONS OF CHOLECYSTCHOLEDOCHAL FISTULA //INTERNATIONAL SCIENTIFIC REVIEW OF THE PROBLEMS OF NATURAL SCIENCES AND MEDICINE. – 2021. – С. 24-32.
31. Курбанов Н. А. и др. Differentiated surgical tactics for Mirizzi syndrome in patients with cholelithiasis //Шпитальна хірургія. Журнал імені ЛЯ Ковальчука. – №. 1. – С. 56-61.
32. Kurbonov N. A. et al. MANAGEMENT OF THE MIRIZZI SYNDROME AND THE SURGICAL IMPLICATIONS OF CHOLECYSTCHOLEDOCHAL FISTULA //INTERNATIONAL SCIENTIFIC REVIEW OF THE PROBLEMS OF NATURAL SCIENCES AND MEDICINE. – 2021. – С. 24-32.
33. Курбонов Н. А., Исматуллаев Ф. Х. ДИФФЕРЕНЦИРОВАННЫЙ ХИРУРГИЧЕСКИЙ ПОДХОД ПРИ СИНДРОМЕ МИРИЗЗИ //EUROPEAN RESEARCH: INNOVATION IN SCIENCE, EDUCATION AND TECHNOLOGY. – 2022. – С. 95-101.
34. Янгиев Б. А. и др. Тактические подходы в современном лечении травматических повреждений печени //Journal the Coryphaeus of Science. – 2023. – Т. 5. – №. 1. – С. 204-210.
35. Нарзуллаев С. И. и др. Синдром внутрибрюшной гипертензии при сочетанных абдоминальных травмах //Journal the Coryphaeus of Science. – 2023. – Т. 5. – №. 1. – С. 211-220.
36. Турсунов О. А. и др. В условиях экстренной медицинской помощи растворы кристаллических аминокислот для дополнительного парентерального питания в интенсивной терапии больных оперированных на желудочно-кишечном тракте //Journal the Coryphaeus of Science. – 2023. – Т. 5. – №. 1. – С. 221-228.
37. Сабиров Б. и др. Лечебно-диагностическая видеолапароскопия в экстренной хирургии //Журнал проблемы биологии и медицины. – 2015. – №. 1 (82). – С. 70-72.
38. Курбонов Н. А., Карабаев Х. К., Нормаматов Б. П. ИЗМЕНЕНИЯ ЛИПИДНОГО ОБМЕНА ПРИ ОЖОГОВОЙ БОЛЕЗНИ У ДЕТЕЙ //Детская хирургия. – 2020. – Т. 24. – №. S1. – С. 47-47.
39. Курбонов Н. А., Карабаев Н. А., Тагаев К. Р. ОЖОГОВЫЙ ШОК У ДЕТЕЙ //Детская хирургия. – 2020. – Т. 24. – №. S1. – С. 48-48.
40. Курбонов Н. А., Давлатов С. С., Рахманов К. Э. OPTIMIZATION OF SURGICAL TREATMENT OF PATIENTS WITH MIRIZZI

SYNDROME //ЖУРНАЛ ГЕПАТО-  
ГАСТРОЭНТЕРОЛОГИЧЕСКИХ ИССЛЕДОВАНИЙ. – 2022. – Т. 3.  
– №. 1.

- 41.Кадыров Р. и др. Эндоскопические методы гемостаза при кровотечении из варикозно расширенных вен пищевода //Журнал проблемы биологии и медицины. – 2017. – №. 4 (97). – С. 44-47.
- 42.Кадыров Р. и др. Сочетанный эндоскопический гемостаз при язвенных кровотечениях //Журнал проблемы биологии и медицины. – 2018. – №. 1 (99). – С. 47-49.
- 43.Курбонов Н., Давлатов С., Амонов М. Modern methods of diagnosis and treatment of patients with Mirizzi syndrome //Журнал вестник врача. – 2021. – Т. 1. – №. 2 (99). – С. 158-161.
- 44.QURBONOV N. A. et al. Current trends in the management of Mirizzi syndrome: A review of literature //Annals of the Romanian Society for Cell Biology. – 2021. – С. 1927-1932.
- 45.Abduraxmanovich A. A. et al. POSSIBILITIES OF APPLYING MINIMALLY INVASIVE TECHNOLOGIES IN TREATMENT OF SEVERE ACUTE PANCREATITIS //Central Asian Journal of Medical and Natural Science. – 2021. – Т. 2. – №. 3. – С. 246-249.
- 46.Курбонов Н. А. и др. MODERN APPROACHES TO THE TREATMENT OF DEEP BURNING PATIENTS //УЗБЕКСКИЙ МЕДИЦИНСКИЙ ЖУРНАЛ. – 2022. – Т. 3. – №. 2.
- 47.Davlatov S. et al. Current State of The Problem Treatment of Mirizzi Syndrome (Literature Review) //International Journal of Pharmaceutical Research. – 2020. – Т. 12. – №. Suppl. ry 2. – С. 1931-1939.